NEURO - OPHTHALMOLOGY COMMON DISORDERS

BY: PROF. DUNERA R. ILAKO

DATE:

Outline

- *Basic Neuro - Ophthalmology*
  - *Visual, reflex and gaze pathways*
  - *Some clinical findings*
    - *Optic neuropathy*
    - *Papilledema*
    - *Disorders of the chiasm*
    - *Ocular motor nerve palsies*
  - *Visual fields interpretations*

Perspective

- *Why is this important*
  - *60% of our brain is linked to vision*
  - *SMALL problems with the eye causes BIG problems for the patient*
  - *EYE problems may be markers for serious SYSTEM problem*
  - *Multidisciplinary approach*

Normal Eye and Optic Disc

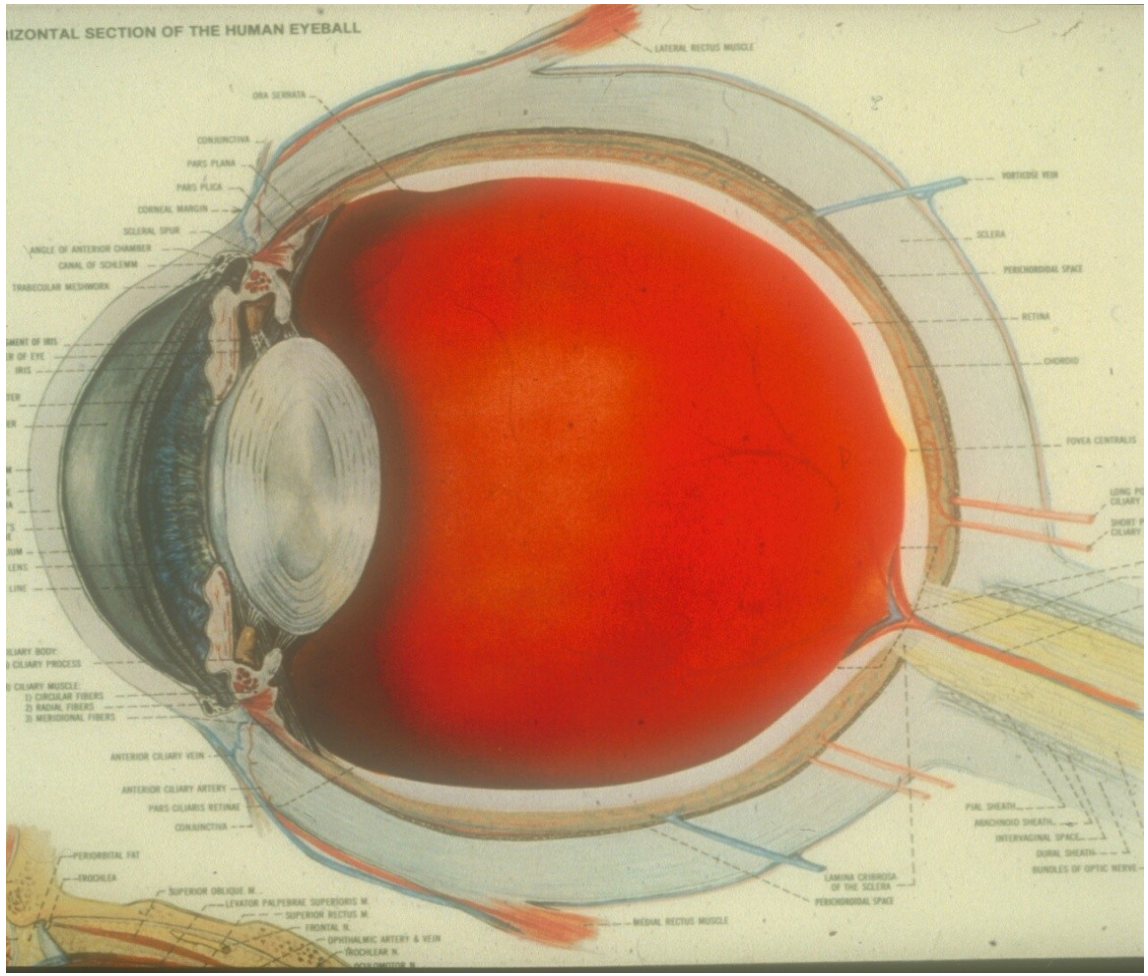

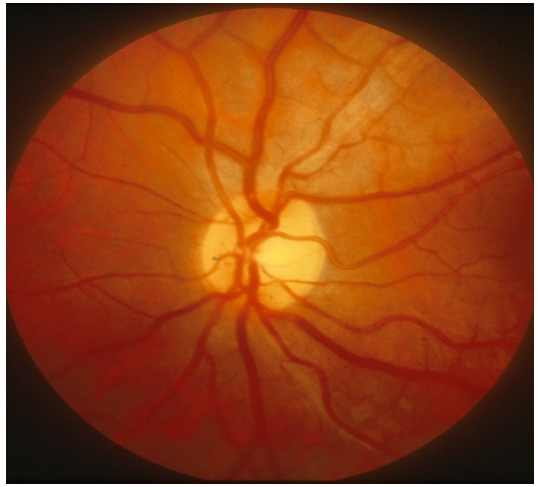

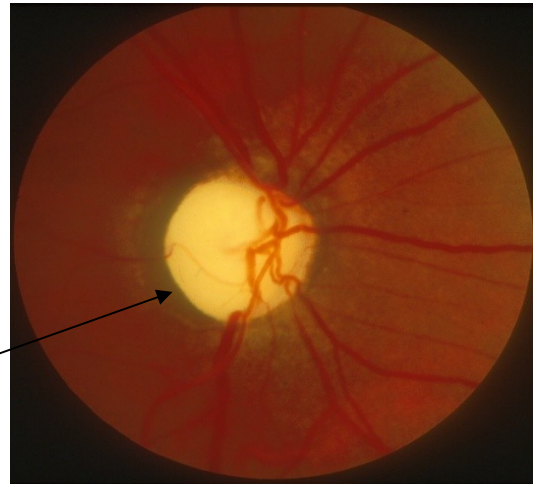

Cupped disc

Basic Visual Pathways

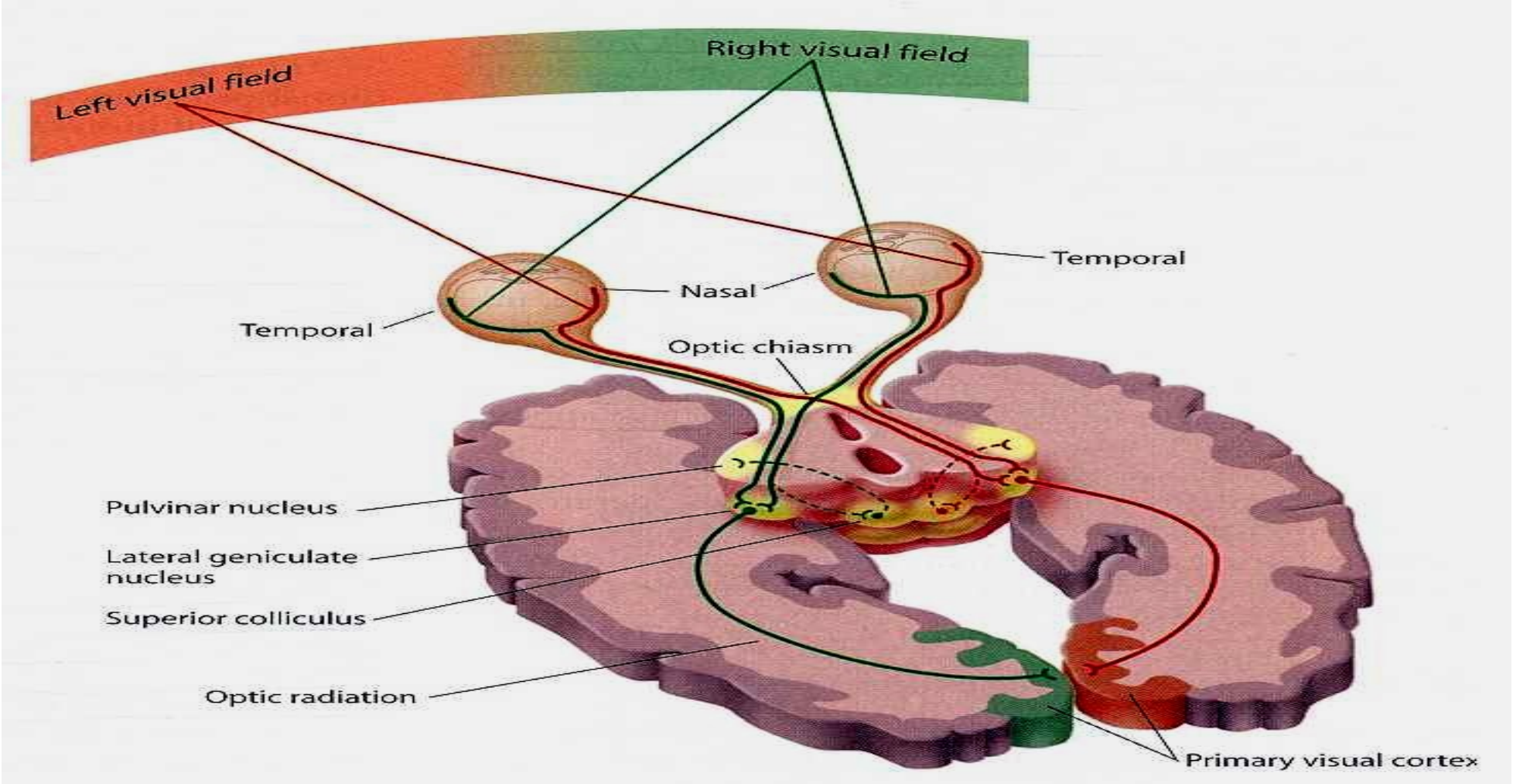

Anatomy - Light reflex

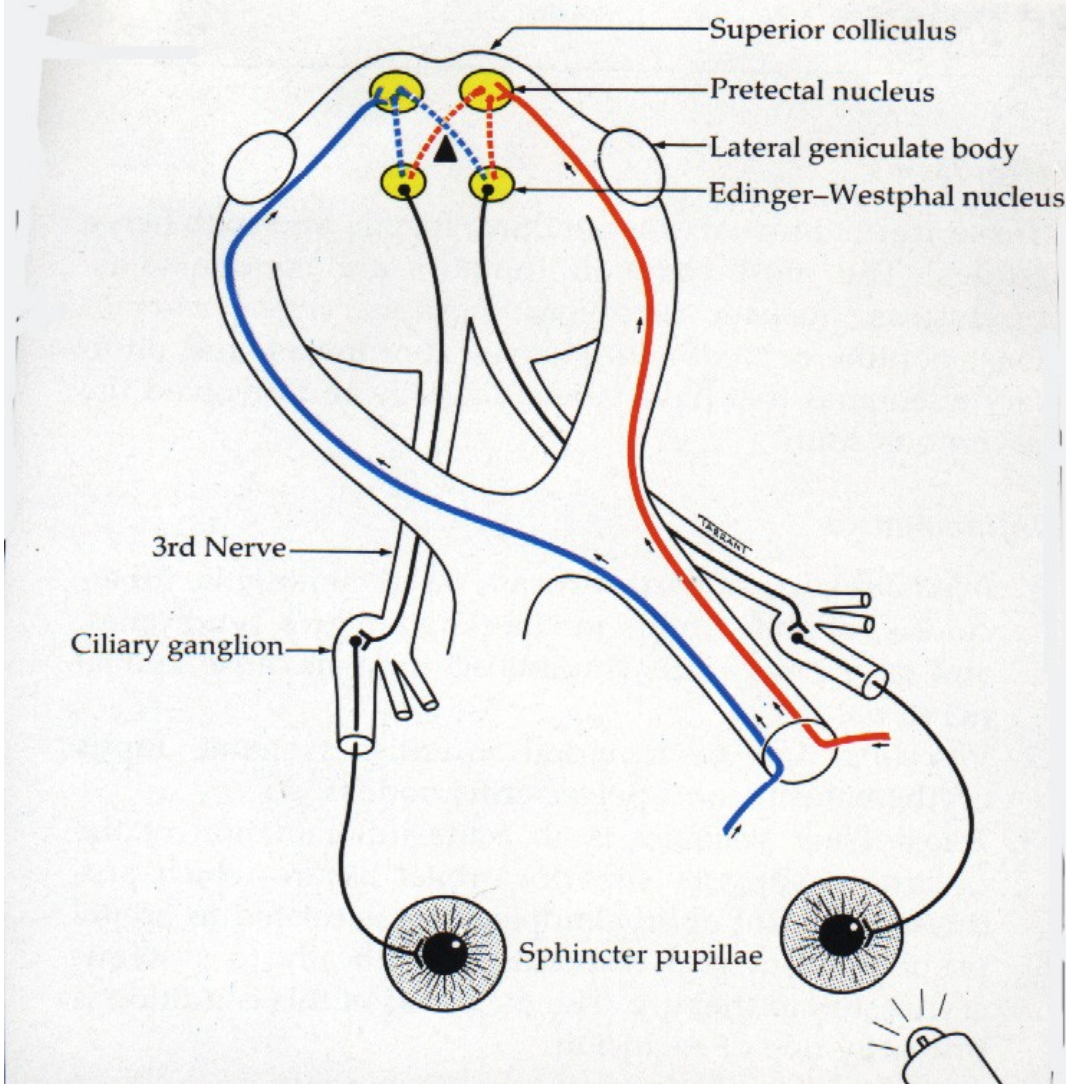

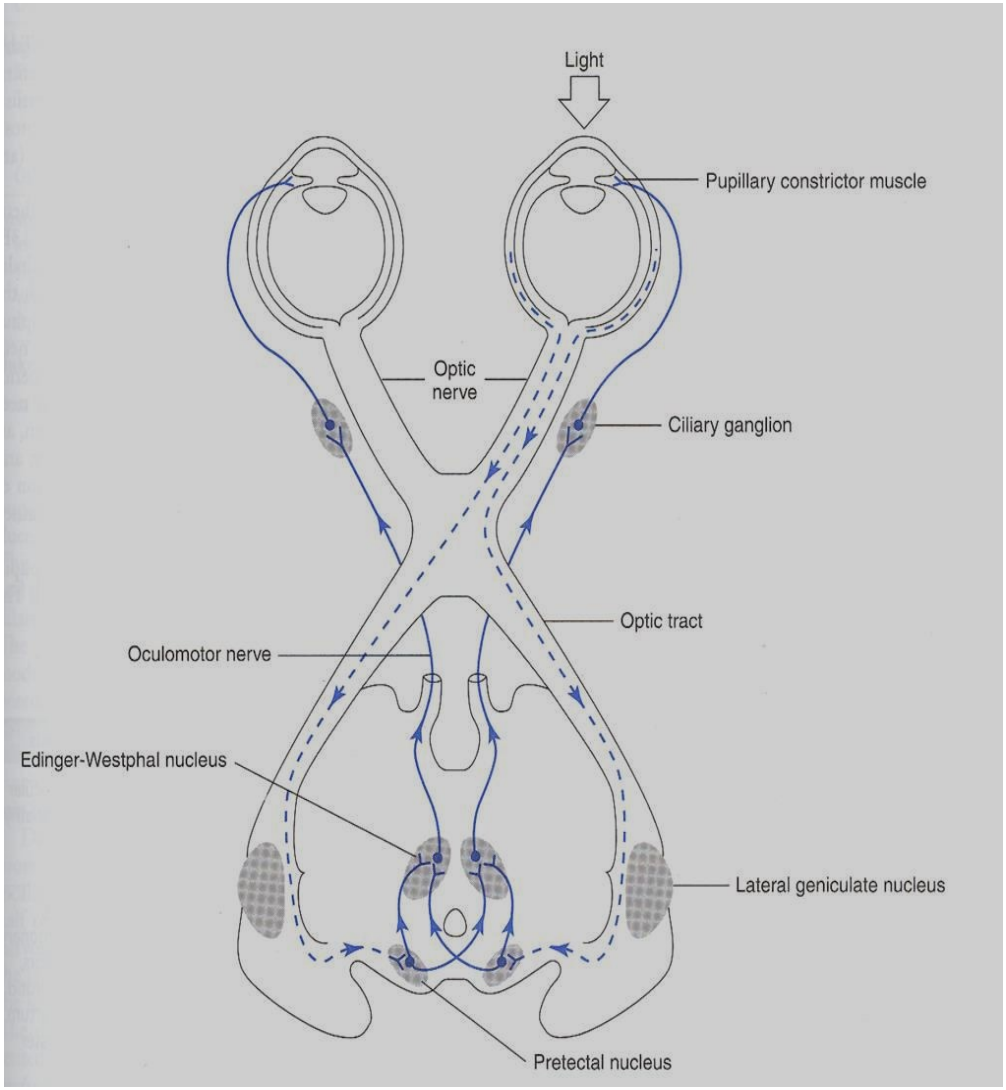

Anatomy of chiasma and pituitary gland

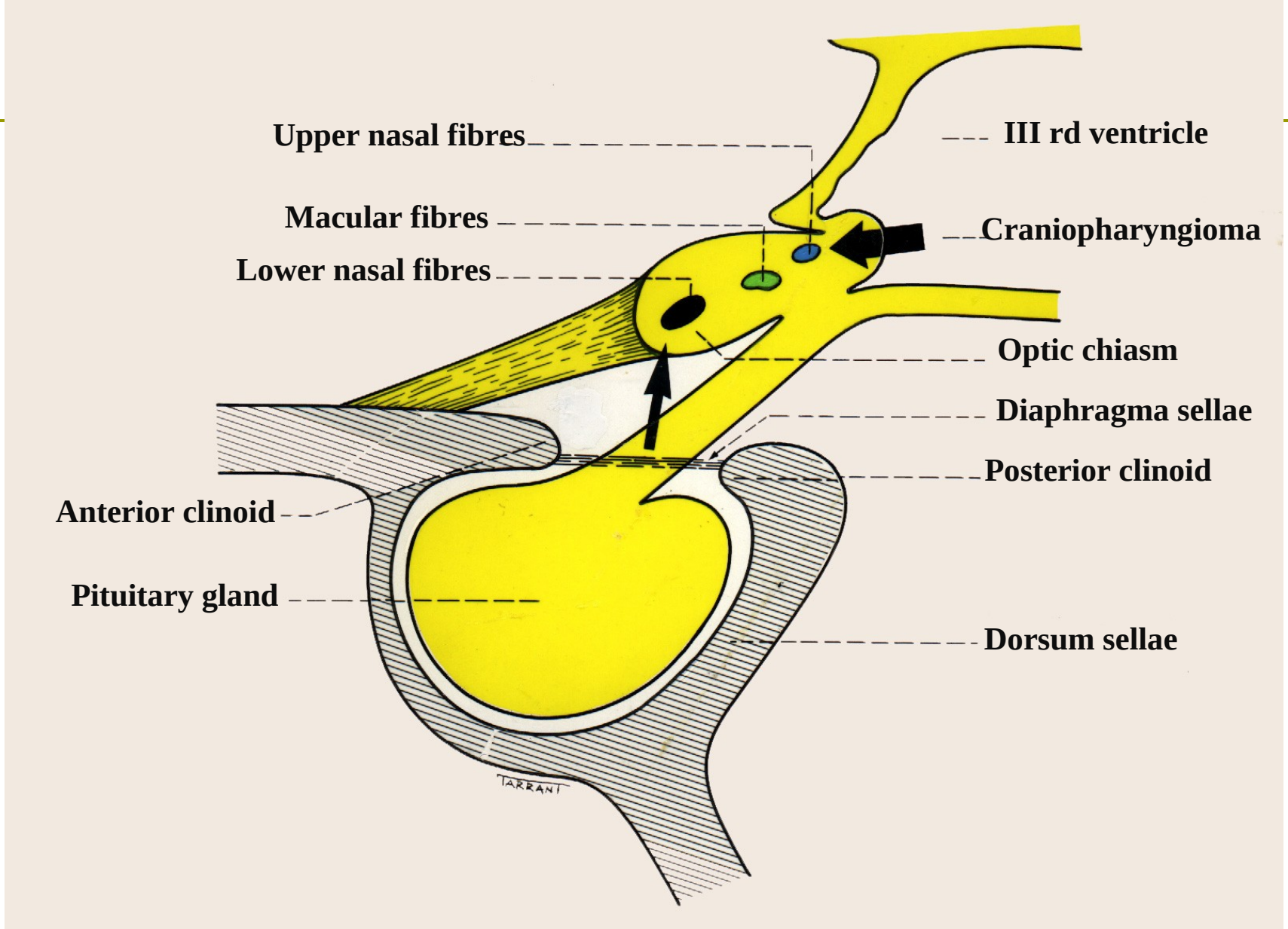

Symptoms -Visual Loss - Blindness

- *Loss of vision*
  - *Transient (*<24hr) e.g. secondary to a TIA
  - *Constant/persistent* (>24 hr)
  - *monocular* - anterior to chiasm
  - *binocular -* posterior to chiasm
- *Diplopia*
  - *Usually secondary to a muscular or a vascular problem*
- *Ptosis.*
- *Visual disturbances.*
- *Pupil irregularities.*
- *Eyelid or Facial spasms spasms*

Transient (<24 hr)

- *Seconds*
  - *Papilledema*
- *Minutes*
  - *TIA (amaurosis fugax) - unilateral*
  - *Vertebro - basilar artery insufficiency – bilateral*
- *Minutes to an hour*
  - *Migraine*
  - *Sudden BP changes*

Persistent (>24 hr)

- *Painful*
  - *Corneal abrasion or ulcer*
  - *Angle closure glaucoma*
  - *Optic neuritis*
  - *Iritis/uveitis*
  - *Keratoconus with hydrops*
- *So, mainly EYE problems*

Neuro - ophthalmological

- *Visual loss not readily explained by an abnormality on physical examination*
- *Pre-Chiasmal (often monocular)*
  - *Optic neuritis*
    - *Comes in various forms:*
      - *Ischemic optic neuritis*
      - *Compressive optic neuritis*
      - *Toxic and metabolic optic neuritis e.g. kumikumi neuritis*

Neuro - ophthalmological

- *Chiasmal*
  - *Chiasmal compression from pituitary or other Intracranial tumours (ICTs)*
  - *Classically bitemporal hemianopia*
  - *SOL's may compress asymmetrically!*
- *Post-Chiasmal*
  - *CVA*
  - *Tumour*
  - *A-V malformation*
  - *Migraine*

Clinical approach

- *Rapid assessment to find and treat reversible conditions.*
- *Consider systemic implications*
- *History: most important thing*
- *Examination*
  - *VA*
    - *If the visual acuity is reduced, do a pinhole test to rule out refractive errors.*
  - *Pupils*
    - *Pupillary reaction tests*

CONT.

- *Fundoscopy*
- *Inspection of the globe (fluoroscein)*
- *Extra-ocular Muscle Motility (EOMM)*
- *Tests*

Clinical Approach

- *History is the most important part or the assessment.*
- *"Where" is the lesion ?*
- *"What" can be the lesion ?*
- *Is this an emergency ?*

Applied anatomy – afferent conduction defect

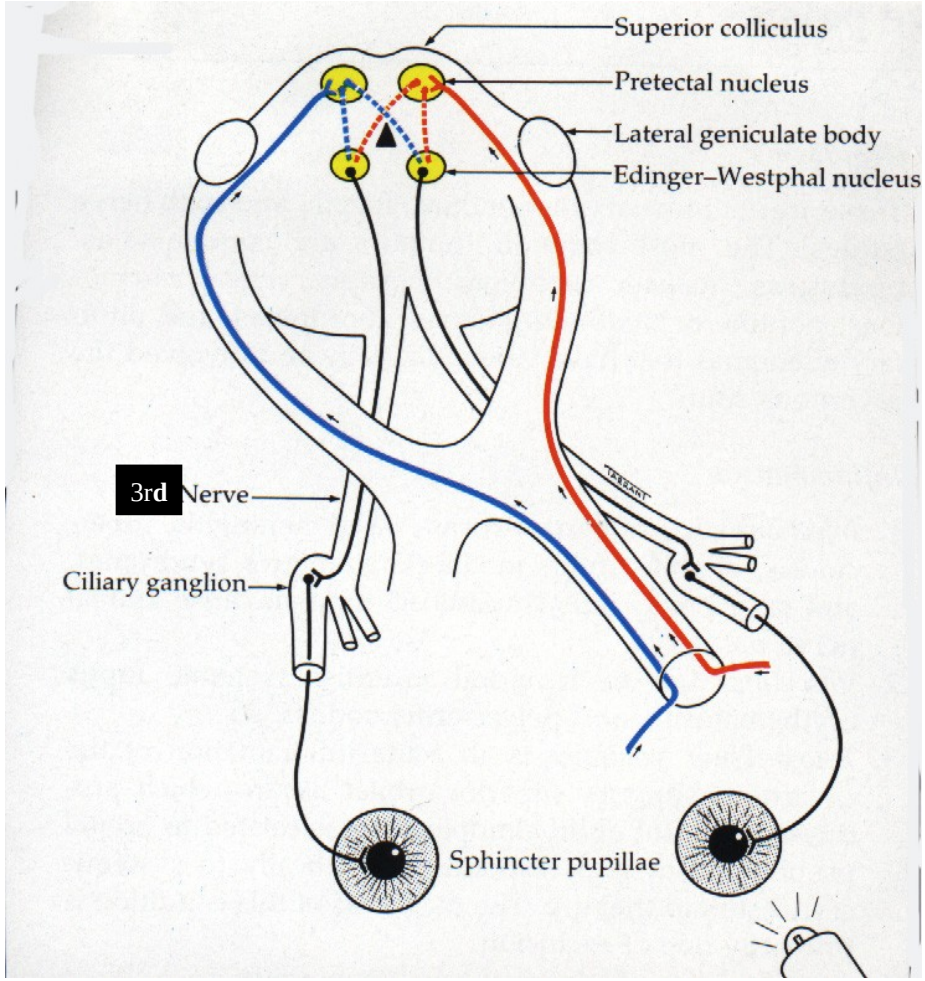

- *Equal pupil size*
- *Light reaction*
  - *Ipsilatral direct is absent or diminished*
  - *Consensual is normal*
- *Near reflex normal in BE*
- *Total defect – amaurotic pupil*
- *Relative – Marcus Gunn*

Pupil

- *Constricted (mioisis)*
  - *Sympathetic (pupillodilator) denervation*
  - *Drugs*
    - *Pilocarpine*
    - *Morphine*
- *Dilated (mydriasis)*
  - *Parasympathetic (pupilloconstrictor) denervation*
  - *Lesion of the third CN*
  - *Drugs*
    - *Atropine*
    - *Cocaine*

Afferent & efferent defects

- *Argyll-Robertson pupil*
  - *Small, irregular*
  - *Does not react to light*
  - *Reacts to accommodation*
  - *Causes*
    - *syphilis*
    - *diabetes*
- *Adie's syndrome - Miotonic pupil*
  - *Dilated*
  - *Poor response to light and convergence.*
- *Constricts - weak Pilocarpine*
- *Holmes-Adie syndrome*
  - *Reduced tendon reflexes (Knee, ankle)*
  - *Orthostatic hypotension*

Horner's

- *Oculosympathetic paresis*
  - *Partial ptosis*
  - *Miosis*
  - *Ipsilateral anhidrosis*
  - *Does not dilate with cocaine 4%*

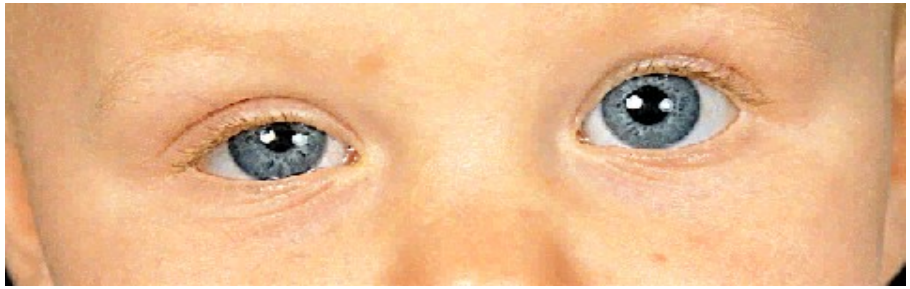

The swollen optic disc

- *Papilloedema/Papillitis*
  - *Malignant hypertension*
  - *Ischemic optic neuropathy*
  - *Diabetic optic neuropathy*
  - *CRVO*
  - *Intraocular Inflammation*

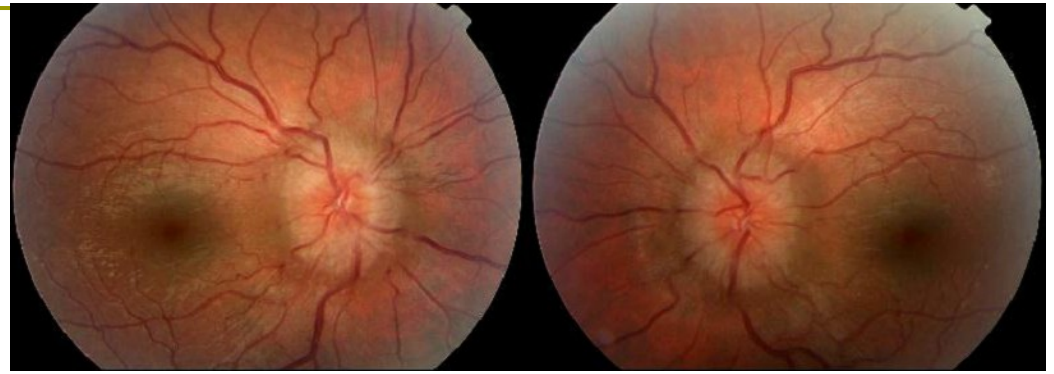

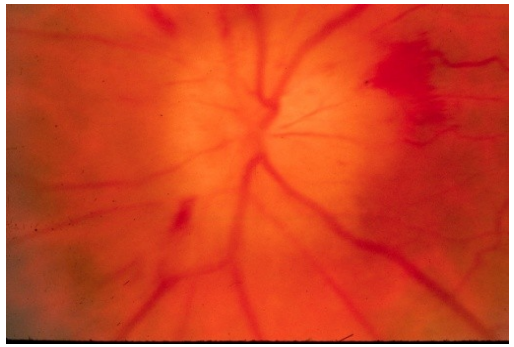

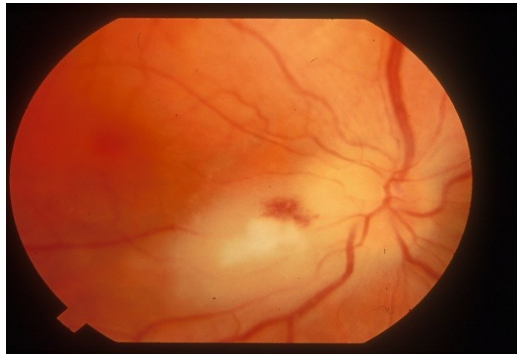

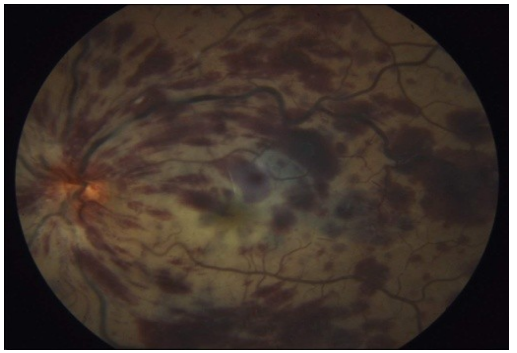

PAPILLEDEMA VS. PAPILLITIS

- Papilledema
  - No pain
  - Usually bilateral
  - Raised ICP is the commonest cause
  - Visual loss initially is not as marked unless it is a chronic process
  - On examination: marked swelling (up to 7 diopters required to focus)
  - Pupillary reaction: normal since the problem is post – chiasmal
  - Visual field: enlarged blind spot
- Papillitis
  - Pain on movement
  - Unilateral often
  - Marked visual loss
  - Definite but not as marked swelling (one can still focus up to about 3 diopters)
  - There will be a relative afferent pupillary defect
  - Visual field: central scotoma

Papilloedema

- *Causes*
  - *Space occupying lesion*
  - *Intracranial hypertension*
    - *Idiopathic*
    - *Drugs*
    - *Endocrine*
  - *Severe hypertension*
- *Disc swelling secondary to raised ICP*

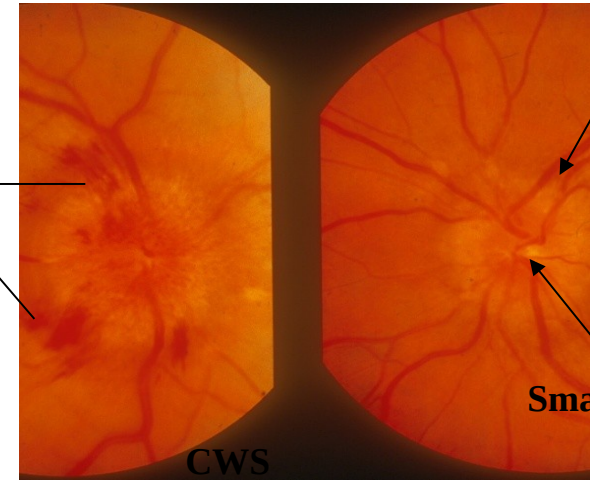

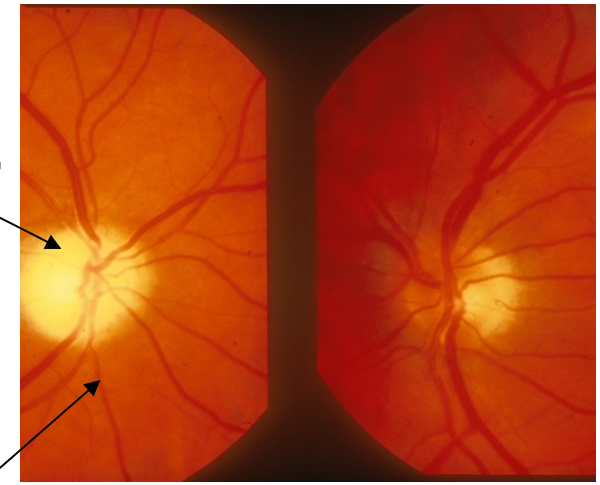

SIGNS & SYMPTOMS

- *Headache*
  - *Worse in the morning*
  - *Valsalva manouver*
- *Nausea and projectile vomiting*
- *Horizontal diplopia (VI palsy)*

ESTABLISHED PAPILEDEMA (ACUTE)

- *VA - usually normal*
- *Severe disc elevation and hyperemia*
- *Very indistinct disc margins*
- *Obscuration of small vessels*
- *Marked venous engorgement*
- *Reduced or absent optic cup*
- *Hemorrhages + cotton-wool spots*
- *Macular star*

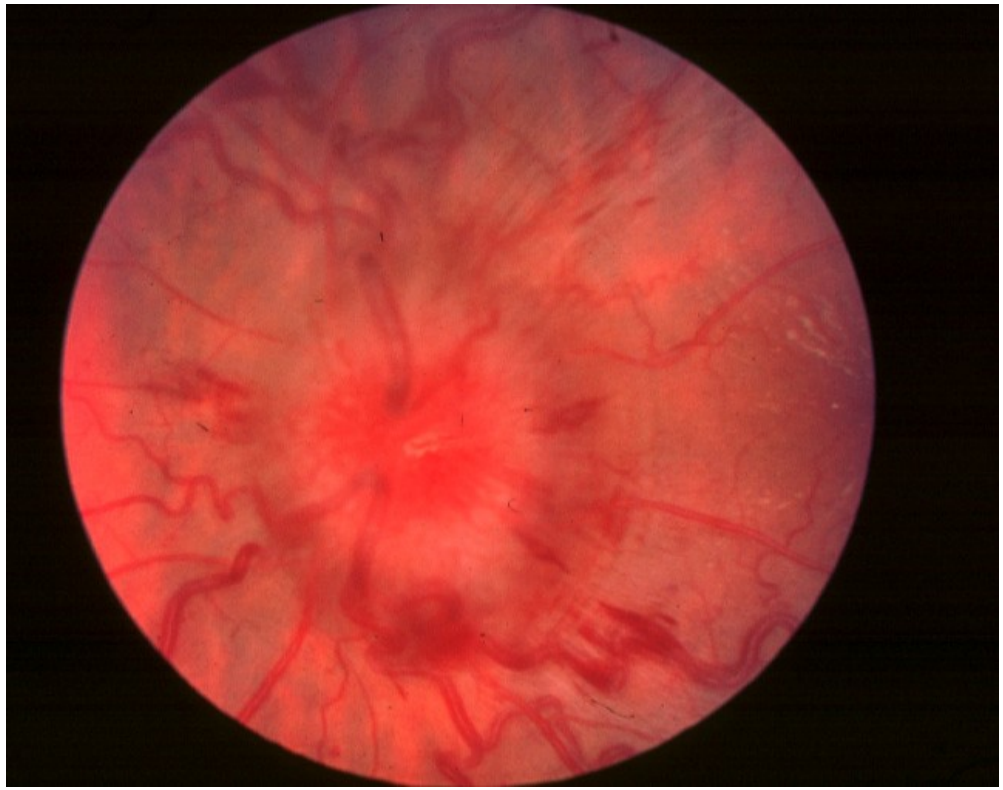

Longstanding papilledema (chronic)

- *VA - variable*
- *Marked disc elevation but less hyperemia*
- *Disc margins - indistinct*
- *Variable venous engorgement*
- *Absent optic cup*

The pale optic disc

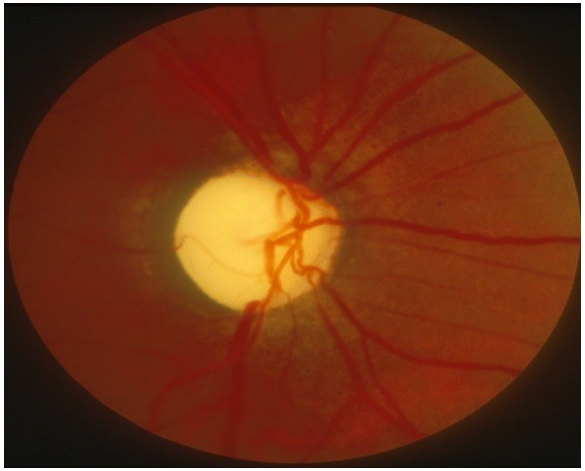

- *Congenital*
- *Secondary*
  - *raised ICP*
  - *vascular retinal dx*
  - *optic neuritis*
  - *optic nerve compression*
  - *trauma*
- *Glaucoma*

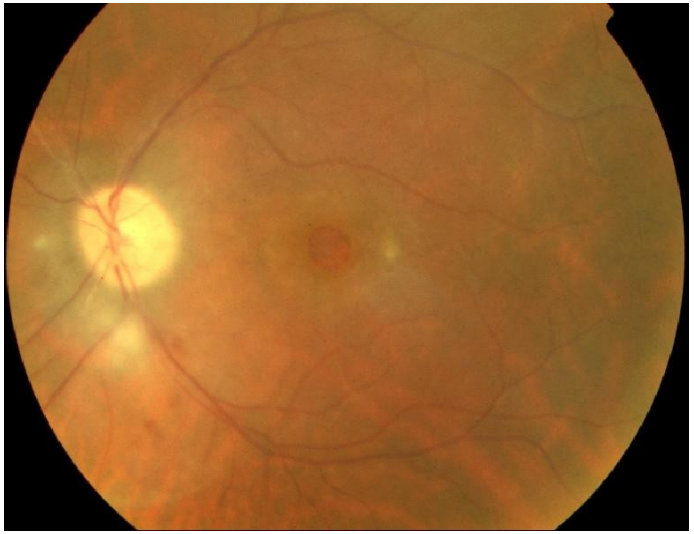

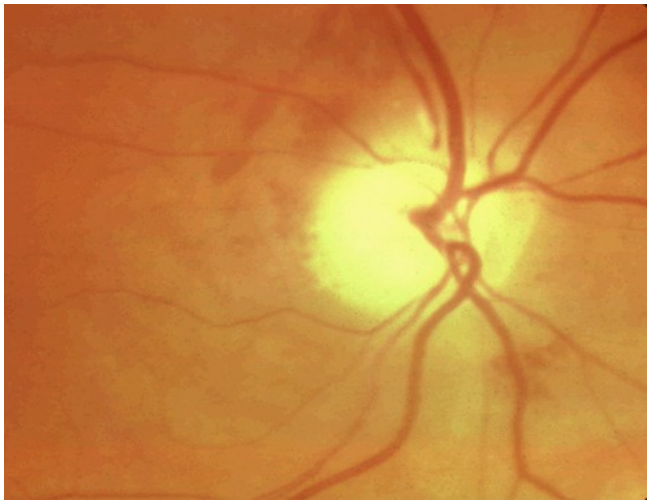

Optic Neuropathies

- *Clinical Features*
- *Special Investigations*
- *Optic Neuritis*
  - *Retro - bulbar neuritis*
  - *Papillitis*
  - *Neuro-retinitis*
  - *Kumi kumi*
- *Ischemic optic neuropathy (arteritic and non-arteritic)*
  - *Demyelinating*
  - *Toxic*
  - *Hereditary e.g. Leber's DNA mutation*

Optic Neuritis

Fundus Exam:

- *May be normal in up to 66% (retro bulbar)*
- *Rest may have:*
  - *Optic disk swelling*
  - *Blurring of disk margins*
  - *Swollen retinal veins*

Treatment

- *Steroids Controversial*
  - *Hastens visual recovery/may delay onset of MS; no benefit beyond 2yr compared to placebo*

“Kumi kumi” optic neuritis

- *Methanol toxicity*
- *Metabolic acidosis*
- *Demyelination then necrosis of the Optic Nerve*
- *“Lights out”*
- *Common in slums and low SES communities*
- *Reversible in early stage (24 - 48 hrs)*
- *Rx: More alcohol (ethanol)*

Ocular Motor nerve Palsies

$$(LR_6 SO_4)_3$$

Ocular motility abnormalities

- *Third nerve palsy*
  - *Double vision*
  - *Eye turned down & out*
  - *Ptosis*
  - *Dilated pupil & headache*
    - *Compressive lesion*
- *Sixth nerve palsy*
  - *Double vision*
  - *Eye turned in*

Cranial Nerve Palsies

Looking straight ahead

Signs of right third nerve palsy

- *Ptosis, mydriasis and cycloplegia*
- *Abduction in primary position*

- *Normal abduction*
- *Intorsion on attempted downgaze*

- *Limited adduction*

- *Limited elevation*

- *Limited depression*

Recent right sixth nerve palsy

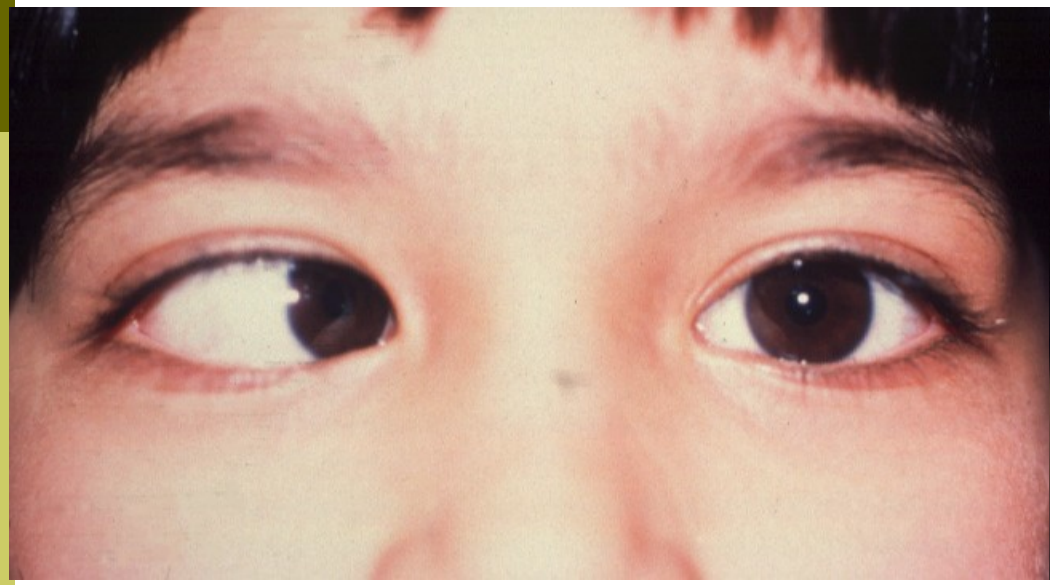

Right esotropia in primary position due to unopposed action of right medial rectus

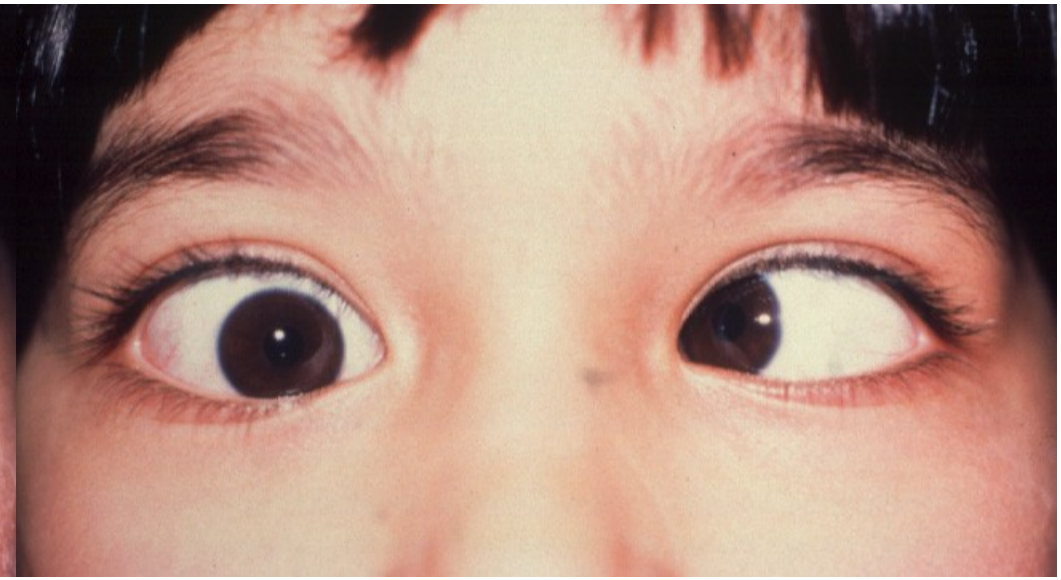

Marked limitation of right abduction due to right lateral rectus weakness

Posterior communicating artery aneurysm

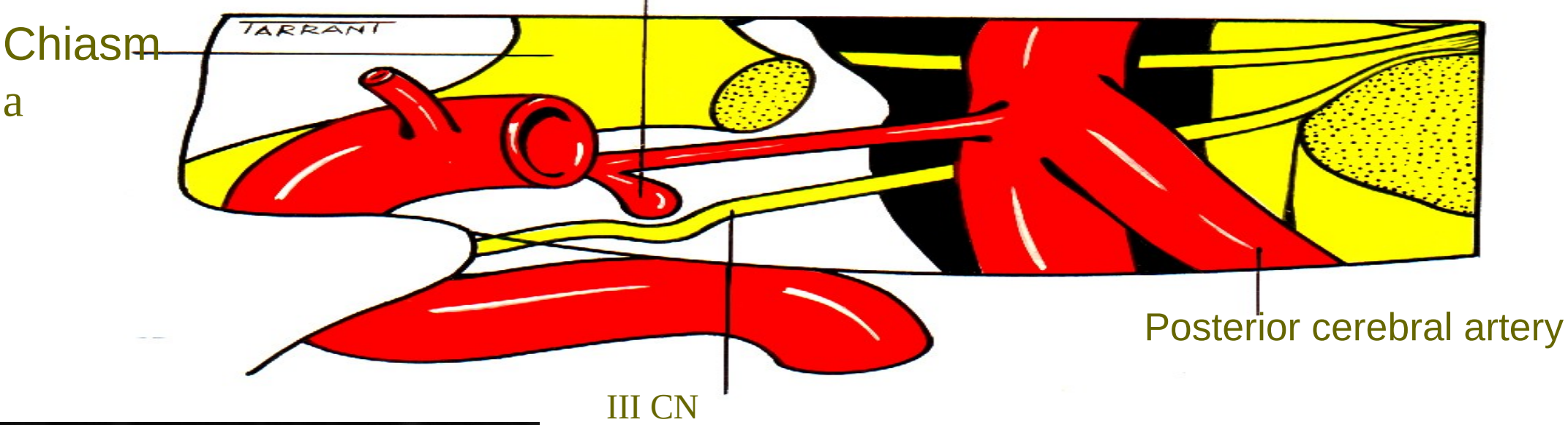

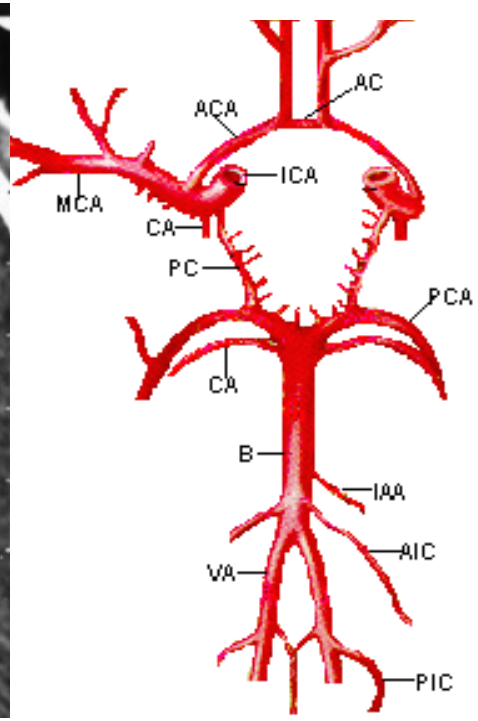

Visual Field by Confrontation

Localising the lesion - VF

- Monocular visual field defects
  - indicate lesions anterior to the optic chiasm
- Bitemporal defects are the hallmark
  - chiasmal lesions
- Binocular homonymous hemianopia
  - result from lesions in the contralateral postchiasmal region
- Binocular quadrantanopias
  - optic tract lesions

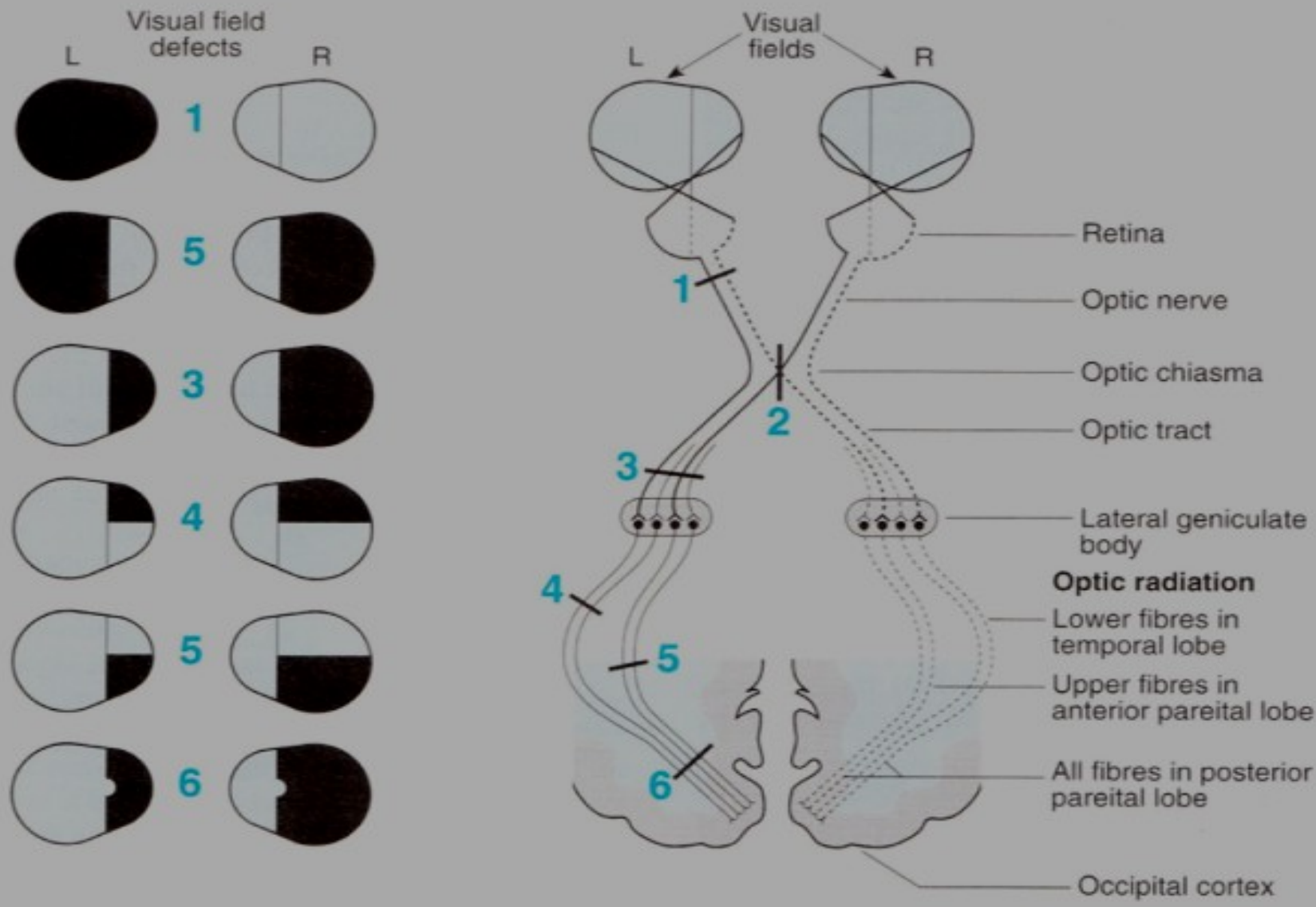

Fig. 7.8 **Visual field defects.** **1.** Total loss of vision in one eye because of a lesion of the optic nerve. **2.** Bitemporal hemianopia due to compression of the optic nerve. 3. Right homonymous hemianopia from a lesion of the optic tract. **4.** Upper right quadrant hemianopia from a lesion of the lower fibres of the optic radiation in the temporal lobe. **5.** Less commonly a lower quadrantic hemanopia occurs from a lesion of the upper fibres of the optic radiation in the anterior part of the parietal lobe. 6. Right homonymous hemianopia with sparing of the macula due to lesion of the optic radiation in the posterior part of the parietal lobe.

Causes of Raised Intracranial Pressure

- Space-occupying lesions
- Blockage of ventricular system
- Obstruction of CSF absorption
- Benign intracranial hypertension -(pseudotumour cerebri)
- Diffuse cerebral oedema
- Hypersecretion of CSF

Myasthenia Gravis

- Signs/symptoms
  - Fatigability
  - Double vision
  - Lid twitch
  - Ptosis
  - Normal reflexes & sensation
- Tests
  - Tensilon test
  - Electromyography
  - Thoracic CT and MRI to rule out thymoma

Superficial temporal arteritis

- Presentation
  - Scalp tenderness
  - Headache
  - Jaw clauduication
  - Polymyalgia rhematica
  - Superficial temporal arteritis
  - Acute visual loss
- Special investigations
  - ESR . 60/20% normal
  - C- reactive Pr always
  - Temporal artery biopsy

Superficial temporal arteritis……

- Steroids (don’t wait for biopsy)
- If any visual disturbance
  - Ophthalmological emergency – try to save the other eye!
  - Initial high dose IV steroids, followed by a year or more of tapering steroids, protects vision
  - Monitor treatment